

## Case Report

## Open Access

## A Singular Case of Adenomyoma of Ampulla with Parathyroid Adenoma - A Rarest of Rare Association

Karthikayan V R<sup>1\*</sup>, Vinay B N<sup>2</sup>, Arun H N<sup>3</sup> and Gautham M V<sup>4</sup>

<sup>1</sup>Senior Resident, Department of Surgical Gastroenterology and Liver transplant, Bangalore Medical College and Research Institute, Bengaluru, India

<sup>2</sup>Professor and Head of Department, Department of Surgical Gastroenterology and Liver transplant, Bangalore Medical College and Research Institute, Bengaluru, India

<sup>3</sup>Associate Professor, Department of Surgical Oncology, Kidwai Memorial Institute of Oncology, Bengaluru, India

<sup>4</sup>Senior Resident, Department of Surgical Gastroenterology and Liver Transplant, Bangalore Medical College and Research Institute, Bengaluru, India

### ABSTRACT

Adenomyoma is an uncommon benign lesion, rare in the extrahepatic biliary tree and ampulla of Vater, but relatively more common in the gallbladder. Preoperative diagnosis of ampullary adenomyoma is highly challenging, as it often mimics malignancy.

We present a case report of a 58-year-old gentleman who presented with abdominal pain and obstructive jaundice to our institution and underwent standard pancreaticoduodenectomy for suspected periampullary malignancy. Surprisingly, the biopsy revealed adenomyoma of the ampulla. Postoperatively, he developed symptoms of hypercalcemia, which, upon further evaluation, was due to a hyperfunctioning left parathyroid adenoma that was subsequently surgically removed.

The coexistence of adenomyoma of the ampulla and parathyroid adenoma is exceedingly rare and has not been reported in the literature to the best of our knowledge. We present this unique case report to highlight this singular association, hoping that further research in the future may shed light on this phenomenon. Serum calcium levels should be assessed in all periampullary lesions, as this simple test could have identified the parathyroid adenoma preoperatively.

### \*Corresponding author

Karthikayan V R, Senior Resident, Department of Surgical Gastroenterology and Liver transplant, Bangalore Medical College and Research Institute, Bengaluru - 560002, India. Email: doctorvrk@gmail.com. Orcid id: <https://orcid.org/0000-0002-5918-0515>.

**Received:** October 17, 2024; **Accepted:** October 22, 2024; **Published:** November 15, 2024

**Keywords:** Adenomyoma Ampulla, Periampullary Malignancy, Parathyroid Adenoma, Hypercalcemia, Case Report

### Introduction

Adenomyoma (adenomyomatous hyperplasia, adenomyomatosis or adenomyosis) is an uncommon hamartomatous benign lesion found throughout the gastrointestinal tract, more commonly in gallbladder and notably rare in common bile duct (CBD) and in ampulla of Vater (AOV) [1]. Adenomyoma of the AOV is clinically significant as it causes obstructive jaundice, mimicking adenocarcinoma of the AOV or distal CBD. Despite being a benign lesion they are mostly treated with major surgical resection with high morbidity, as preoperative diagnosis is extremely challenging.

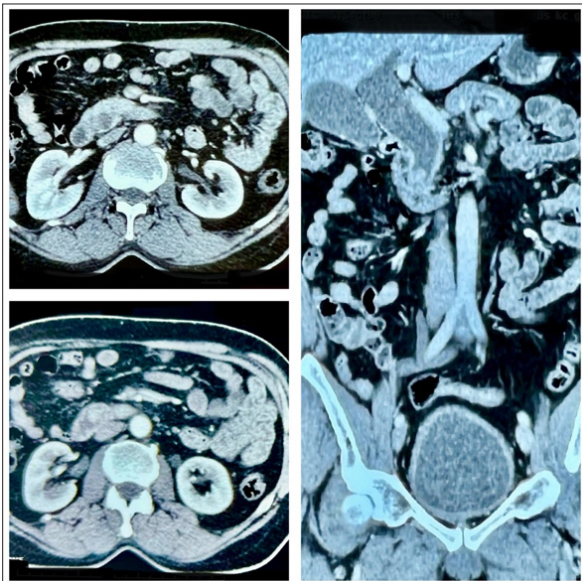
We report a case of a 58 year old gentleman with adenomyoma ampulla who was treated with standard pancreaticoduodenectomy (PD) without any major post operative surgical complications. Surprisingly, the patient developed complications from hypercalcemia, caused by a newly detected parathyroid adenoma. This case report highlights both the rarity and diagnostic challenge

of adenomyoma of the AOV, as well as the fact that its coexistence with parathyroid adenoma has not yet been reported in the literature.

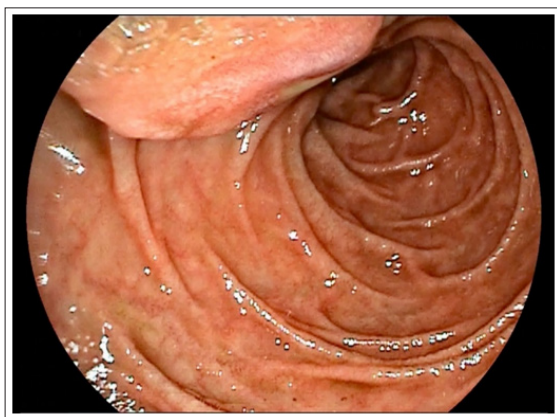### Case Presentation

A 58-year-old male patient with no comorbidities presented to our institution with complaints of upper abdominal pain for 2 months and yellowish discoloration of eyes for 2 weeks. He had no history of colicky flank pain, bony pain, polyuria, psychosis or any other neuro psychiatric symptoms. There was no family history of any malignancies. Laboratory workup showed a deranged obstructive pattern liver function test with total bilirubin of 3.4 mg/dl, direct bilirubin of 2.8 mg/dl, alkaline phosphatase (ALP) of 330 U/L and normal alanine transaminase (ALT) and aspartate transaminase (AST). Complete blood count was normal, with no elevation of acute phase reactants and a normal amylase level. Cancer antigen 19-9 (CA 19-9) and carcinoembryonic antigen (CEA) were normal. Abdominal contrast enhanced computed tomography (CECT) scan showed a heterogeneously enhancing soft tissue lesion of size 1.5 x 1.4 x 1.3 cm, located in the ampullary region with upstream

dilation of CBD of 30 mm and intrahepatic biliary radicles dilation (IHBRD) and dilated main pancreatic duct of 4 mm (Figure 1). There was also an incidentally detected right kidney upper pole microlith. Upper gastrointestinal (GI) scopy revealed bulging of ampulla with normal mucosa (Figure 2). Biopsy was not performed since a negative or inconclusive biopsy would not change the treatment plan of the patient as suspicion of malignancy was high.

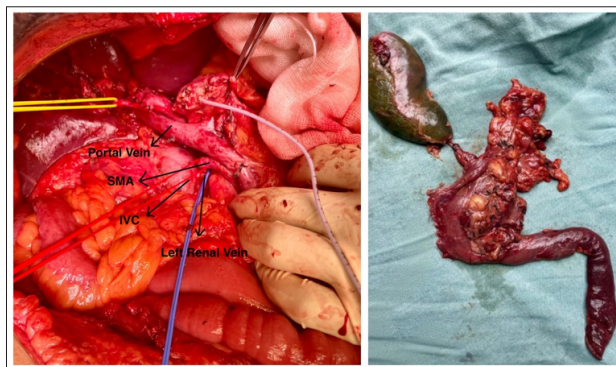


**Figure 1:** Axial and coronal view of computed tomography shows enhancing lesion in ampulla with dilated common bile duct.

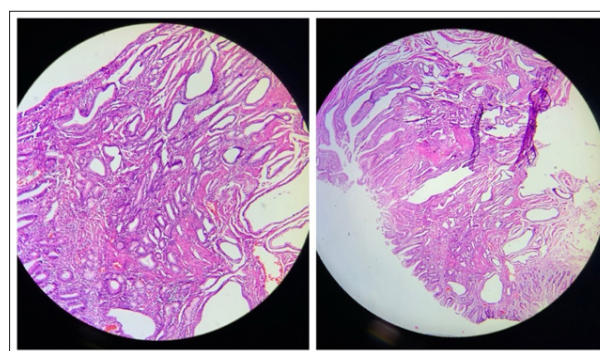


**Figure 2:** Esophagogastroduodenoscopy showing bulging of ampullary region with normal mucosa covering it

This case was reviewed in a multidisciplinary gastrointestinal (GI) oncology meeting, and after discussion with the patient, an open standard pancreaticoduodenectomy (PD) was performed (Figure 3). He had a smooth post-operative course with no major complications. The resected specimen showed 1.5 x 1.5 x 1 cm nodule at the ampulla that on microscope showed a well-circumscribed nodular proliferation of ducts, glands and smooth muscle cells in a disorganized pattern diagnostic of adenomyoma of ampulla (Figure 4).

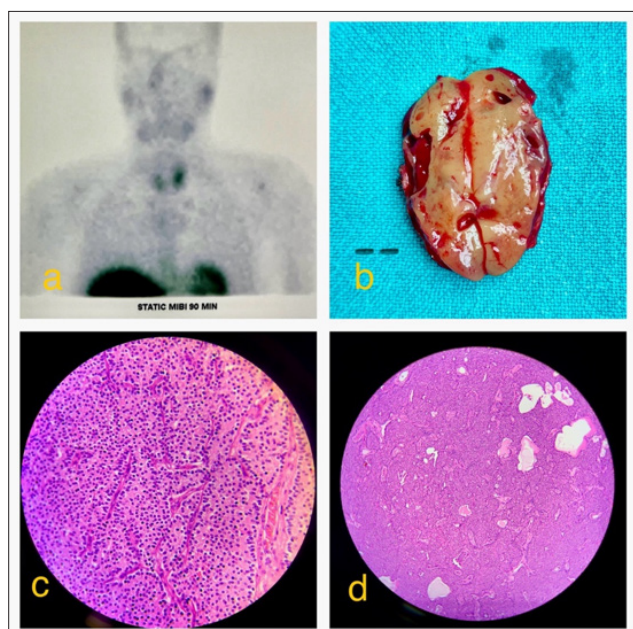


**Figure 3:** Intraoperative image showing vascular structures after Pancreaticoduodenectomy (Left) and Standard Pancreaticoduodenectomy Specimen (Right). SMA – Superior Mesenteric Artery, IVC – Inferior Vena Cava.



**Figure 4:** Histopathological imaging - hematoxylin and eosin staining shows nodular proliferation of ducts, glands and smooth muscle cells in a disorganized pattern without any atypia or mitosis, suggestive of adenomyoma of ampulla

On post-operative day (POD) 7 patient was irritable, talking irrelevantly and developed mild slurring of speech. On evaluation he was found to have severe hypercalcemia (total serum calcium of 15.8 mg/dl) and on further investigation, was found to have primary hyperparathyroidism (increased serum parathyroid hormone levels of 663 pg/ml; normal range 10-65 pg/ml). Ultrasonography of the neck revealed a well-defined lesion of 3 x 3 x 1.6 cm in the left parathyroid region. Endocrinology consultation was done, and he was evaluated for associated Multiple endocrine neoplasia (MEN) syndrome. Magnetic resonance imaging (MRI) brain was normal with normal prolactin, growth hormone levels and normal thyroid function test. He was found to have none of the associated features of MEN syndrome. Technetium-99m Sestamibi (MIBI - methoxy isobutyl isonitrile) parathyroid scan and MIBI- pertechnetate subtraction study confirmed the diagnosis of left parathyroid adenoma (Figure 5 a). After optimizing the patient, surgery to remove the left parathyroid adenoma was done, and biopsy confirmed the same (Figure 5 b,c,d). He was discharged in stable condition, and he is symptom free and on regular follow up for the last 8 months.



**Figure 5:**  
**5a** - Sestamibi scan showing increased tracer uptake in left parathyroid region with persistent hold up till delayed images.  
**5b** - Cut open specimen of left parathyroid adenoma.  
**5c** (40x Magnification) and  
**5d** (10x Magnification)-hematoxylin and eosin-stained microscopy images shows a benign neoplasm composed of chief cells with granular cytoplasm and round vesicular nucleus admixed with areas of hemorrhage and cystic change, consistent with parathyroid adenoma.

### Timeline

Day	Events
0	Patient presented to the hospital with abdominal pain and yellowish discoloration of eyes
5	Multidisciplinary GI oncology meeting – suspected periampullary malignancy and final decision for surgery made
7	Open standard pancreaticoduodenectomy surgery was done with no major complications
14	POD 7 – he was irritable and talking irrelevantly
17	Sestamibi scan confirmed the diagnosis of left parathyroid adenoma
19	Left parathyroidectomy was done
23	Patient discharged in stable condition

### Discussion

Adenomyomas are defined as duct-like structures with hyperplasia of smooth muscle cells, combining both epithelial and mesenchymal elements [2]. Adenomyoma is relatively more common in gallbladder and extremely rare in AOV with less than 60 cases being described

in indexed literature so far, reported mostly as single case reports [3, 4]. The exact histogenesis of adenomyoma in AOV is still unknown with two common hypotheses attributing to their origin. One states that chronic inflammation of papilla causes both muscular and adenomyomatous hyperplasia while the other one hypothesize that these lesions might be incomplete heterotopic pancreatic tissue [5].

Preoperative diagnosis of adenomyoma of AOV is highly challenging as its presentation mimics that of periampullary malignancy. Radiological imaging (CECT, MRI, MRCP) doesn't reliably differentiate them, as both appear as tumor like mass in ampullary region with upstream biliary dilatation [3]. Diagnosis is confirmed only by histological examination, which is not always possible on endoscopic biopsies as overall accuracy is low [6]. Menzel et al in their prospective study of 40 patients with papilla of Vater tumors, concluded that in case of enlarged or suspicious papillae, endoscopic biopsies from both deep and superficial layers following sphincterotomy should be obtained to improve diagnostic accuracy. In a 10-year retrospective study by Gamble et al. of AOV biopsy specimens from 252 patients, many benign ampullary biopsies were later found to be malignant upon resection, indicating that a negative endoscopic biopsy does not rule out malignancy in ampullary lesions [7]. In our patient this is the reason we didn't proceed with endoscopic biopsy and directly went ahead with PD surgery. Although a few reports suggest that endoscopic papillectomy or surgical ampullectomy is sufficient for these benign ampullary lesions, most patients undergo Whipple procedure and are diagnosed definitively as adenomyoma only after the final biopsy (Table 1) [4]. Choosing the appropriate treatment in these cases is highly challenging, because both radiology and endoscopy often cannot accurately distinguish between benign and malignant ampullary lesions as shown in the below table (Table 1).

Serum calcium levels are not routinely checked in the preoperative evaluation of these patients if kidney function tests are normal, particularly in resource-limited settings like the Indian subcontinent. Our patient is unique in that he had no symptoms of hypercalcemia preoperatively but developed them post-surgery. An incidental CECT finding of a right kidney microlith, was not further evaluated as the patient was asymptomatic. In retrospect, assessing this asymptomatic microlith with serum calcium levels could have led to a preoperative diagnosis of the parathyroid adenoma, potentially reducing overall morbidity.

Association of hyperfunctioning parathyroid adenoma with ampullary lesions is very rare, although association with Gastro-Entero-Pancreatic (GEP) neuroendocrine tumor is reported in MEN type 1 syndrome [12]. Our patient had a normal MRI brain and pituitary hormone levels with negative GEP neuroendocrine workup. Despite extensive literature search, the association of adenomyoma of ampulla with a hyperfunctioning parathyroid adenoma has not yet been reported and further research might be needed to shed some light on this unique association.

**Table 1: Literary Review of Similar Case Reports of Adenomyoma of Ampulla**

Authors	Age /Sex	Clinical presentation	LFT	Imaging/ Endoscopy	Preoperative biopsy	Treatment
[8]	61/M	Upper abdominal pain	Obstructive pattern (elevated direct bilirubin and ALP)	CT: acute pancreatitis with dilatation of CBD and dilated pancreatic duct. EUS: multilobulated hypoechoic ampullary density (2.4 × 2.1 cm).	EUS-FNA: reactive cells. Endoscopic biopsies: inflammatory polyp versus inflammatory changes	Endoscopic ampullectomy
[9]	42/M	Jaundice and upper abdominal pain	Obstructive pattern	CT: abrupt narrowing of the distal CBD and proximal biliary dilatation.	Endobiliary biopsies: chronic inflammation with fibrosis and dysplastic change	PD
[5]	73/F	Jaundice	Obstructive pattern	MRCP: stenosis of the distal CBD at ampullary level, with dilatation above this region. EUS: retro-ampullary mass.	Endoscopic biopsies: atypical cells and chronic inflammation without dysplasia	PD
[3]	58/M	Upper abdominal pain	Mildly elevated transaminases with normal bilirubin and ALP	Endoscopy: bulging papilla. EUS: mass in the ampullary region.	EUS-FNA: epithelial cell groups, some with benign characteristics, others in favour of epithelial dysplasia	PD
[10]	74/F	Incidentally detected for evaluation of renal colic pain	Normal	CT: nodular lesion in distal CBD with proximal biliary dilation and dilated MPD and left renal tumor. MRCP: ampullary mass causing bicanalar obstruction.	Not done	PPPD with partial nephrectomy
[11]	47/F	Abdominal pain	Obstructive pattern	CT: mild extrahepatic biliary dilation with diffuse wall thickening and smooth distal CBD tapering.	Endoscopic biopsy: chronic inflammation with no atypical cells	PPPD
Our case	58/M	Upper abdominal pain and jaundice	Obstructive pattern	CT: ampullary mass with proximal biliary dilation and dilated MPD with right kidney microlith.	Not done	PD

LFT- Liver Function Test  
CT- Computed Tomography  
CBD- Common Bile Duct  
EUS- Endoscopic Ultrasound  
FNA- Fine Needle Aspiration  
PD- Pancreaticoduodenectomy  
MRCP- Magnetic Resonance Cholangiopancreatography  
ALP- Alkaline Phosphatase  
MPD- Main Pancreatic Duct  
PPPD- Pylorus Preserving Pancreaticoduodenectomy

### Conclusion

Adenomyomas of the AOV and distal CBD are rare benign lesions, typically diagnosed through postoperative biopsies, as they often mimic malignant neoplasms and rarely receive a definitive preoperative diagnosis from radiology or endoscopy. There are currently no established guidelines or protocols for evaluating and managing this condition. Urgent research is needed to implement newer techniques, such as EUS, immunohistochemistry (IHC), and advancements in frozen sections and pathology, to improve diagnostics and enhance patient outcomes.

Serum calcium levels should be assessed in all periampullary lesions, as this simple test could have identified the parathyroid adenoma preoperatively, especially given the patient's kidney microliths. This case highlights the importance of thoroughly evaluating even minor incidental findings before major resections, even if the patient is asymptomatic.

### Abbreviations

CBD - Common Bile Duct  
AOV - Ampulla of Vater  
PD - Pancreaticoduodenectomy  
CECT - Contrast Enhanced Computed Tomography  
POD - Post Operative Day  
MEN - Multiple Endocrine Neoplasia  
MRI - Magnetic Resonance Imaging  
MRCP - Magnetic Resonance Cholangiopancreatography  
EUS - Endoscopic Ultrasound

### Declaration of Conflicting Interests

The authors declare that there is no conflict of interests regarding the publication of this case report.

### Informed Consent For Publishing

Obtained from the patient concerned.

### Ethical Approval

Not applicable /not necessary at our institution to publish an anonymous case report.

**Funding: Nil/Not Applicable**

Acknowledgements: Nil

### References

1. Handra-Luca A, Terris B, Couvelard A, Bonte H, Flejou JF (2003) Adenomyoma and adenomyomatous hyperplasia of the Vaterian system: clinical, pathological, and new immunohistochemical features of 13 cases. *Modern pathology* 16: 530-536.
2. Albores-Saavedra J, Adsay NV, Crawford JM, Klimstra DS, Kloppel G (2010) World Health Organization Classification of Tumors of the Digestive System. World Health Organization classification of tumours 2010: 266-273.
3. Gouveia C, Fidalgo C, Loureiro R, Oliveira H, Maio R, et al. (2021) Adenomyomatosis of the common bile duct and ampulla of Vater. *GE-Portuguese Journal of Gastroenterology* 28: 121-133.
4. Choi YH, Kim MJ, Han JH, Yoon SM, Chae HB, et al. (2013) Clinical, pathological, and immunohistochemical features of adenomyoma in the ampulla of vater. *The Korean Journal of Gastroenterology* 62: 352-358.
5. Gialamas E, Mormont M, Bagetakos I, Frossard JL, Morel P, et al. (2018) Combination of adenomyoma and adenomyomatous hyperplasia of the ampullary system: a first case report. *International journal of surgical pathology* 26: 644-648.
6. Menzel J, Poremba C, Dietl KH, Böcker W, Domschke W (1999) Tumors of the papilla of Vater—inadequate diagnostic impact of endoscopic forceps biopsies taken prior to and following sphincterotomy. *Annals of Oncology* 10: 1227-1231.
7. Gamble D, Frankel WL, Yearsley MM, Chen W (2023) Ampulla of Vater biopsies: A retrospective 10-year, single-institution study. *Annals of Diagnostic Pathology* 67: 152189.
8. Tanimu S (2014) Adenomyomatous hyperplasia of the ampulla of Vater presenting as acute pancreatitis. *Case Reports* 6: bcr2013203151.
9. Choi JH, Lee SH, Kim JS, Kim J, Shin BS, et al. (2016) A case of adenomyomatous hyperplasia of the distal common bile duct mimicking malignant stricture. *The Korean Journal of Gastroenterology* 67: 332-336.
10. Frutuoso L, Pereira AM, Carvalho L, Gonçalves G, Nora M (2021) Adenomyomatous Hyperplasia of Ampulla of Vater and a concomitant renal Tumor: a Case Report. *Cureus* 13.
11. Kwon HJ, Kim SG, Park J (2023) Adenomyoma of the ampulla of Vater mimicking malignancy: A case report and literature review. *Medicine* 102: e34080.
12. Singh G, Mulji NJ, Jialal I (2023) Multiple Endocrine Neoplasia Type 1. In *StatPearls* [Internet] 2023 Jul 10. StatPearls Publishing <https://pubmed.ncbi.nlm.nih.gov/30725665/>.11.

**Copyright:** ©2024 Karthikayan VR, et al. This is an open-access article distributed under the terms of the Creative Commons Attribution License, which permits unrestricted use, distribution, and reproduction in any medium, provided the original author and source are credited.