

Case Report

Open Access

Acrorenal Syndrome: Case Series

Abhinav Gupta*, Mohd Iqbal bhat and Isha Kaul

Department of Medicine, Acharya Shri Chander College of Medical Sciences and Hospital Jammu, India

ABSTRACT

Acral (limb) and renal anomalies occur together as a single developmental field defect or as components of several malformation syndromes. The embryogenesis of that defect was studied experimentally by Lash and the developmental relationship between kidneys and limbs has been reviewed by Buchta and Gilbert. The acral anomalies consist of split hand/ split foot, varying combination of oligodactyly, ectrodactyly, syndactyly, brachydactyly, polydactyly or fusion of carpal, tarsal, metatarsal bones of hands and feet. Urinary tract dysplasias are renal agenesis, duplication, ureteral hypoplasia, polycystic kidneys, hydronephrosis and bladder neck obstruction. The authors report three cases of acrorenal syndrome and discuss its clinical and laboratory findings.

*Corresponding author

Abhinav Gupta Department of Medicine, Acharya Shri Chander College of Medical Sciences and Hospital Jammu, India. Tel: 9419196020.

Received: August 07, 2023; **Accepted:** August 17, 2023; **Published:** August 23, 2023

Keywords: Acrorenal Syndrome, Limb Defects, Pigmentary Retinopathy, Renal Failure

Introduction

Acral (limb) and renal anomalies occur together as a single developmental field defect or as components of several malformation syndromes. The embryogenesis of that defect was studied experimentally by Lash [1]. and the developmental relationship between kidneys and limbs has been reviewed by Buchta and Gilbert [2,3]. The acral anomalies consist of split hand/ split foot, varying combination of oligodactyly, ectrodactyly, syndactyly, brachydactyly, polydactyly or fusion of carpal, tarsal, metatarsal bones of hands and feet. Urinary tract dysplasias are renal agenesis, duplication, ureteral hypoplasia, polycystic kidneys, hydronephrosis and bladder neck obstruction. The authors report three cases of acrorenal syndrome and discuss its clinical and laboratory findings. The association of limb deformities and renal malformations has been described in different reports under the term acrorenal syndrome [4-8]. The renal anomalies vary from mild anatomical malformations to severe renal hypoplasia and renal failure [4]. The underlying renal pathology associated with renal failure has mainly been described as oligomeganephronia [4-10]. Presentation with end-stage renal failure is rarely reported [6-11].

Case Report 1

A 10 year old consanguineous male presented to ASCOMS Hospital, Jammu with severe left flank pain and reduced urine output. On physical examination, in addition to left costovertebral angle tenderness, an extra thumb on bilateral hands and few external skin tags on his ears were prominent as a congenital anomaly. His genitourinary examination revealed a pair of

completely descended normal appearing testis. Skeletal survey showed congenital reduction deformities of both feet. Abdominal ultrasonography revealed bilaterally small kidneys with altered CMD. The bipolar measurement of right kidney was 4.5cm and left kidney as 4.3cm. There was no similar history in his family. On investigation, Haemoglobin was 9 gm/dl, TC of WBC was 13000/mm, platelet count 160000/mm [3]. Serum creatinine was 3 mg/dl, sodium was 134 mEq/L, potassium was 4.8 mEq/L. His visual acuity and fundus examination was reported to be normal. His echocardiography revealed no significant heart anomalies. He was managed on the lines of chronic kidney disease and is being followed up with renal function tests periodically.



Figure 1: Showing Polydactyly

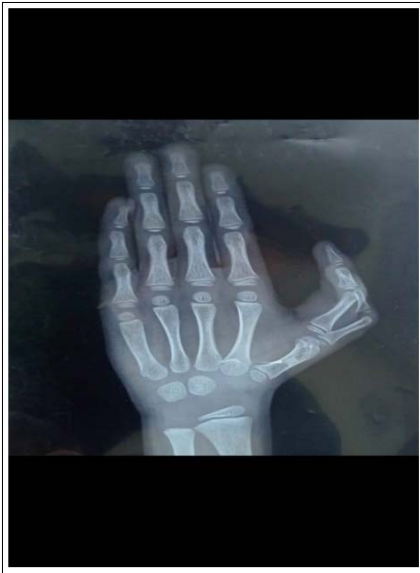

Figure 2: Showing Radiologic Evidence of Polydactyly




Figure 3: Showing External Ear Tags

Case report 2

A 46 year old diabetic female presented to ASCOMS HOSPITAL, Jammu with severe left flank pain, swelling of bilateral lower limbs and reduced urine output. The findings on physical examination included left costovertebral angle tenderness, bilateral pedal edema, presence of extra toe. Intellectual development was normal as per age. Skeletal survey revealed polydactyly in right foot and right hand. Laboratory investigations revealed: urea 140 mg/dl, creatinine 4 mg/dl, sodium 136 meq/l, potassium 4.6 meq/l, calcium 9 mg/dl, phosphorus 6.8mg/dl, hemoglobin 6.1 g/dl, WBC Count of 9800/mm and HbA1C 7.1%. Abdominal ultrasonography showed a normal liver, enlarged spleen (19 cm) and multiple calculi in both kidneys, largest in right kidney measuring 7.2 mm and largest in left kidney measuring 11 mm with no hydronephrosis. Bipolar measurement of the right kidney was 8.9cm and left kidney 8.3 cm. Her Echocardiogram was normal. Deformed hands and feet were noticed immediately after birth, but no major illnesses were reported in the first 3 years of life. Thereafter, she was noticed to have bilateral vision loss and fundus examination which was done later revealed pigmentary retinopathy. Surgical opinion was sought for nephrolithiasis and she was managed conservatively with blood transfusion and adequate hydration with close follow up of renal function tests.

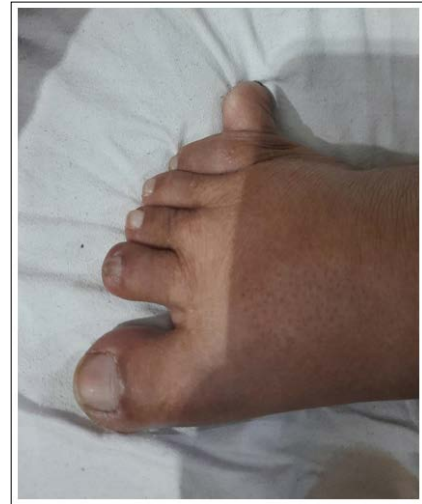


Figure 4: Showing Polydactyly of Feet

Case Report 3

An 8 year old non-consanguineous male child, mainly asymptomatic apart from mild persistent abdominal pain presented with his abdominal ultrasonography revealing non visualised right kidney in right renal fossa or any other ectopic location and a normal appearing left kidney with the bipolar measurement of 9.8 cm. The abdominal examination was consistent with the ultrasonographic findings as no renal mass could be palpated on bimanual palpation on the right side. However, the left kidney was normally palpated. His general physical examination revealed few hypopigmented macular areas on his face and neck. His skeletal survey showed congenital malformations of hands and feet. Deformed hands and feet were noticed right after birth but no major illnesses were reported till 4 years of age. Thereafter, he appeared to be lethargic and pale. His IQ is however normal for his age. Thorough history taking revealed right undescended testis that had been surgically corrected at 2 years of age. There were no similar renal or skeletal abnormalities in his family. His visual acuity and fundus examination was normal. His investigations showed Hemoglobin of 9.2 g/dl, WBC count of 7800/mm creatinine of 1.9 mg/dl, urea of 54 mg/dl, sodium 138 meq/l, potassium of 4.0 meq/l. His echocardiogram was normal. He is currently being managed symptomatically with a close follow up of renal function tests.

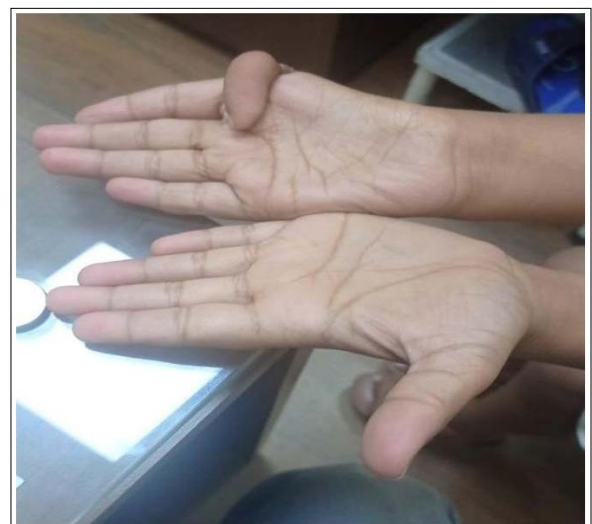

Figure 5: Showing Malformation of Hands

Discussion

Acrorenal syndrome has been described by different observers since the detailed description of Curran and Curran [11]. reported the severe limb deformities being common to all reported cases [4-7]. The lower limbs were more severely affected than the upper limbs in the majority of cases described. The pathogenesis has been linked to an abnormal epithelial-mesenchymal interaction during embryonic development [12]. Such interaction is crucial to the formation of the apical-ectodermal ridge subsequent limb development and to the development of ureteric bud. This is also involved in the morphogenesis of the palate, jaw, skin derivatives, the mammary glands, the paramesonephric ducts and the eye. Zeier et al. [8] reported an adult with acrorenal syndrome in whom the limb defects were more in the upper than the lower limbs. Renal involvement in our patients was severe, as in other cases studied. In our patients, the upper and lower limb defects were equal in incidence and severity. The reported renal involvement in acrorenal syndrome varies from mild hydronephrosis with duplex system to severe bilateral renal hypoplasia and renal failure. Renal pathology has not been frequently described, but the majority of patients who had renal biopsies had oligomeganephronia [7,8,10]. Oligomeganephronia is associated with extremely small kidneys; the kidneys of our patients were also severely hypoplastic [9]. Cryptorchidism and hypospadias are common associations with other renal anomalies and present in about 50% of males with acrorenal syndrome [8,11].

References

1. Lash JW (1964) Normal embryology and teratogenesis. Am J Obst Gynecol 90: 1193-1207.
2. Buchta RM, Viseskul C, Gilbert EF, Sarto GE, Opitz JM (1973) Familial bilateral renal agenesis and hereditary renal adysplasia. Z Kinderheilkd 11: 111-129.
3. Gilbert EF, Opitz JM (1979) Latteinte in the renal hereditary malformation syndromes. Ch 44 In Hamburger et al (eds); Addresses Nephrologic, Volume 2 Paris. Flammarion 936-970.
4. Evans JA, Vitez M, Czeizel A (1992) Patterns of acrorenal malformation association. Am J Med Genet 44: 413-419.
5. Barnes EG, Opitz JM (1992) Renal abnormalities in malformation syndromes. In: Edelmann CM Jr (Ed) Pediatric kidney disease, 2nd edn. Little Brown, Boston 1067-1119.
6. Akle K (1994) Acrorenal syndrome in a child with renal failure. Am J Med Genet 49-447.
7. Miltenyi M, Czeizel AE, Balogh L, Detre Z (1992) Autosomal recessive acrorenal syndrome. Am J Med Genet 43: 789-790.
8. Zeier M, Tariverdian G, Waldherr R, Andrassy K, Ritz E (1989) Acrorenal syndrome in an adult presentation with proteinuria, hypertension and glomerular lesions. Am J Kidney Dis 14: 221-224.
9. Bernstein J (1992) Renal hypoplasia and dysplasia. In: Edelmann CM Jr (ed) Pediatric kidney disease, 2nd edn, Little Brown, Boston 1121-1137.
10. Buttiens M, Fryns JP (1987) apparently new autosomal recessive syndrome of mental retardation, distal limb deficiencies oral involvement and possible renal defect. Am J Med Genet 27: 651-660.
11. Curran AS, Curran JP (1972) Associated acral and renal malformations: a new syndrome? Paediatrics 49: 716-725.
12. Evans JA, Phillips S, Reed M, Chodirker BN (2000) Severe acrorenal-uterine-mandibular syndrome. Am J Med Genet 93: 67-73.

Copyright: ©2023 Abhinav Gupta, et al. This is an open-access article distributed under the terms of the Creative Commons Attribution License, which permits unrestricted use, distribution, and reproduction in any medium, provided the original author and source are credited.