

Short Communication
Open Access

Pseudopolyposis Ulcerative Colitis: An Unusual Finding

 Derqaoui Sabrina^{1,3*}, Bakali Youness^{2,3}, Sabbah Farid^{2,3}, Hrra Abdelmalek^{2,3} and Bernoussi Zakiya^{1,3}
¹Department of Pathology, Ibn Sina Teaching Hospital, Rabat, Morocco

²Department of Surgery C, Ibn Sina Teaching Hospital, Rabat, Morocco

³Faculty of Medicine, Mohamed V University, Rabat, Morocco

***Corresponding author**

Sabrina Derqaoui, Department of Pathology, Ibn Sina Teaching Hospital, Abderrahim Bouabid Avenue, Rabat, Morocco.

Received: August 02, 2024; **Accepted:** August 12, 2024; **Published:** August 16, 2024

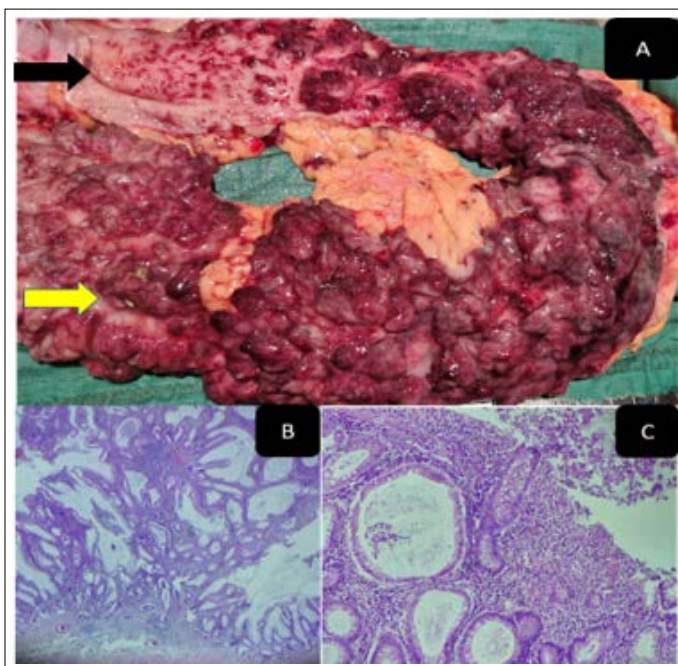
Comment

Diffuse inflammatory polyposis of the colon is a rare finding in Inflammatory Bowel Disease (IBD). Herein we describe a unique case of diffuse giant inflammatory polyposis in 39-year-old women, admitted to the department of surgery for undetermined pancolitis without history of IBD. Gross examination revealed diffuse giant polyps ranging from 0,5 to 2cm sparing the ceacum (Figure A). Extensive sampling was performed to rule out malignancy. Histology showed inflammatory polyps with marked acute inflammation and hyperplastic cystically dilated glands (Figures B and C).

Consent: Informed consent was obtained from the patient 's guarantor

Guarantor: Corresponding Author

Availability of Data and Materials: Not applicable

Authors' Contributions: All authors read and approved the final manuscript

Acknowledgments
Competing Interests: The authors declare that they have no competing interests

Funding: No funding source was needed

Ethics Approval and Consent to Participate: Not applicable

Copyright: ©2024 Derqaoui Sabrina, et al. This is an open-access article distributed under the terms of the Creative Commons Attribution License, which permits unrestricted use, distribution, and reproduction in any medium, provided the original author and source are credited.